



Wenzhou Central Hospital

The DingLi Clinical Institute Affiliated To Wenzhou Medical College

Medical Records for Admission

Name: Wang Yuxuan **Ward:** Obstetrics **Bed Number:** 103009 **Admission Number:** 988260

General Information for Hospital Record

Name : Wang Yuxuan	Post Code : N/A
Sex : Female	Address : Sanyu village, Wengyang street, Leqing city, Wenzhou, Zhejiang province
Age : 28	Identification No: 103009
Marital status : Married	Race : Han nationality
Contact Number : 19975302335	Place of birth: Sanyu village, Wengyang street, Leqing city, Wenzhou, Zhejiang province
Date of Admission : 2023-07-30 12:39	Occupation : None
Complainer of History : Myself	

Chief Complaint: 9+ months after menopause, abdominal pain for 5+ hours.

History of the Present Illness:

Previous menstruation regular, cycle 32-35 days, menstrual period 7 days, menstrual volume is medium, color dark red, painless meridians. Last menstruation: 2022-10-23, due date: 2024-07-30. The form of conception: naturally, the urine pregnancy test was positive on 30+ days after menstruation. 2023-01-12 in Yueqing third people's hospital showed that "single fetus survived, such as 11 weeks+5 days of gestation". Pregnancy has been established in the North White Elephant Health Center in Yueqing city, Wenzhou. Early pregnancy reaction was not obvious to this day. There were no obvious abnormalities in early screening, noninvasive DNA, ultrasonic screening of fetal system, glucose tolerance test, blood pressure and so on. In the trimester of pregnancy, there was no headache, dizziness, no chest tightness, palpitation, no skin pruritus and no edema of lower extremities 35 weeks of pregnancy in Yueqing third people's hospital delivery examination showed that "single fetal survival, such as pregnancy 32W+5D, fetal neck umbilical cord around the neck, amniotic fluid index:87mm", considering "fetal growth restriction may", "heparin sodium injection (Faramine) 5000IV subcutaneous injection once a day" until 38 weeks of pregnancy, fetal growth rate can be. Before 5+ hours in the home without obvious inducement to appear lower abdominal pain, paroxysmal, no radiation to other places, no vaginal fluid, with vaginal red. The clinic intends to "G1PO pregnancy 40+ week LOA parturition. It was found that "hypothyroidism" for 5+ months, regular use of "Youjiale tablets 50u 8once a day" so far, regular review of thyroid function, control can be.

Past Medical history:

General health: good. History of infectious diseases: denial of tuberculosis, denial of hepatitis.

History of disease: He was highly myopic with 950•L and 1000•R respectively. Deny any history of hypertension, heart disease, diabetes mellitus, cerebrovascular disease, nephropathy, liver disease, lung disease.

Vaccination history: unknown, last vaccination date: unknown.

Surgical history: denial. History of injury: denial. History of poisoning: denial. History of blood transfusion: denial.

Allergies:denied. Allergen: denial of food, drug allergies.

Long-term medication history: see history of present illness.
Addictive:denied.

Review of Systems:

Check out the cerebrovascular system, cardiovascular system, respiratory system, lymphatic system, genitourinary system, genital system thorowly and steadily.

Personal history:

Birthplace: Yongjia country , Wenzhou city , Zhejiang province, growing experience: Yongjia country, Wenzhou city, Zhejiang province, living area: Yongjia country, Wenzhou city, Zhejiang province; time: long term. Denied the epidemic area, epidemic situation, water contact history, denied pastoral areas, mines, high fluorine area, low iodine area living history, occupation: unemployed, denied chemical substances, dust, radioactive substances, toxic substances contact history, denied the history of drug use, denied the history of travel. Denied smoking history. Denied drinking history. Family marriage: harmony.

Marital, Menstrual and Childbearing history:

13 years old 32-35 2022-10-23, regular menstrual cycle, moderate menstrual volume, normal color. No blood blots, no pain.

History of marriage: Married at 24. Denied consanguineous marriage. Husband, 28, in good health. Reproductive history: 0-0-0-0

Family History:

Father is alive. The mother is alive. The younger brother was healthy and denied the similar history and infectious disease history with the patient. Deny high blood pressure, blood disease, asthma, gout, diabetes mellitus, epilepsy, congenital dysplasia, mental illness, etc. Height 148cm

Physical Examination

T 36.9 C **P** 95 /min **R** 20 /min **BP** 115/68mmHg

General Appearance:

Postural autonomy no. Weight 53kg

Skin and Mucosa:

Skin mucous membrane without yellow dye, no edema, no rash subcutaneous hemorrhagic, subcutaneous nodules, addiction marks.

Superficial lymph nodes: preauricular, postauricular, mastoid, neck, supraclavicular, armpit, groin, popliteal and other parts of the superficial lymph nodes were not swollen.

Head and HEENT: No external deformities

Normal hearing

Conjunctival anhyperemia and edema

No yellow sclera pupil isometric, diameter 3 mm, sensitive to light reflection

Unobstructed nasal ventilation No tenderness of paranasal sinuses

No tenderness of mastoid

Oral mucosa without hyperaemia, erosion, ulcer

No swelling of tonsills

Neck:

Soft neck Trachea centralisation

No palpable enlargement of the thyroid gland

Jugular vein without agitation

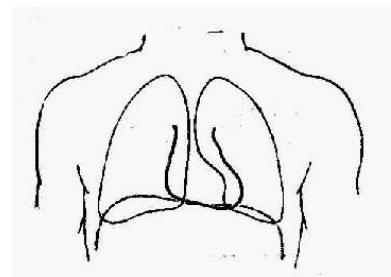
Chest: No deformity of thorax

No widening or narrowing of intercoastal space, bilateral symmetrical breast without mass

Lungs:

Inspection: Bilateral symmetry of respiratory movement

Palpation: No mass palpable



Percussion: Voiceless

Auscultation: Clear breadth sounds in both the lungs, without dry and wet rales.

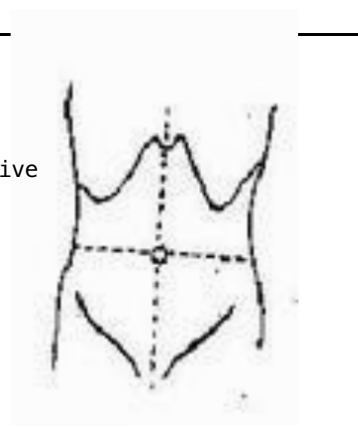
Cardiac Border Diagram

Heart:	Heart rate 95 beats/min	Cardiac arrhythmia	Right	Intercostal	Left
	Murmurs unheard and pathological murmurs		Border (cm)	Space	Border (cm)
				II	
				III	
				IV	
				V	

Blood Vessel: Peripheral vascular negative

Abdomen: Flat shape
Tenderness no
Rebound pain none
Mass missed
The liver is untouched
Spleen untouched under ribs

External genitalia no pain, ulcer, swelling, deformity
Peristaltic wave, no gastrointestinal type and peristaltic wave, abdominal wave firmness soft
No palpable gallbladder enlargement, Murphy's sign negative



Genitourinary system:

Kidney area no percussion
Shifting dullness negative

Bowel sounds 3 times/min

Rectum and Anus:

No scars or ulcers

Extremities and Spine: Normal physiological curvature of the spine, no deformity, no rigidity, knock tenderness, normal range of motion

No deformity of limbs
Joint pain without tenderness and swelling
No edema of lower extremities

Neural System:

Limb muscle V
No increase or decrease in muscle tone
Bilateral knee tendon reflex +1

Other Physical Signs:

Kernig sign negative, lesegue sign negative

Specific Appearance:

Uterine height:34cm, abdominal circumference:90cm, convergence into the basin, fetal heart rate 152 bpms.
Contractions: regular, weak, lasting 25 seconds, intermittent for 4-5 min.
Internal examination: 1cm dilation, 100% cervical receptivity, 2 protrusions, unbroken membranes.
Estimated fetal weight:3000g

Special Examination:

Auxiliary examination: Thyroid gland stimulating hormone (TSH):2.636IU/m, 2023-06-28 Group B streptococci (GBS) were not detected.

Labs Data:

(2023-07-28) Our hospital fetal B-ultrasound: fetal head is located on the pubic symphysis. Biparietal diameter 89mm, head circumference 317mm, abdominal circumference 326mm, femoral diameter 66mm. The placenta is located in the posterior wall of the uterus, maturity grade II, amniotic fluid index 105mm. Due to the fetal structure is not clear. Single head position fetus survived.

(2023-07-30)Fetal cardiac care: normal NST.

Primary Diagnosis:

1. G1P0 pregnancy 40+1 week LOA parturition.
2. Gestational hypothyroidism in the thyroid gland.
3. Pregnancy induced vibration combined with high mucous.



Intern's Signature:

Date(Y/M/D): 2023/08/11

Guide Teacher's Signature :

Score (5分制):
